



Original Article

## Comparison of Intra-Articular Injection and Arthroscopic Capsular Release in Stages I and II of Primary Frozen Shoulder, a Randomized Clinical Trial

Qi Zhu, Yao Jiang, Haiming Wang<sup>\*</sup>, Yaohua He

Department of Orthopaedic Surgery, Shanghai Sixth People's Hospital, Shanghai JiaoTong University, Shanghai, China

### ARTICLE INFO

Accepted 31 July 2018

#### Keywords:

frozen shoulder,  
arthroscopic release,  
intra-articular steroid injection

### SUMMARY

**Background:** To compare the effects of conservative steroid injection and arthroscopic capsular release during early intervention of stages I and II of primary frozen shoulder (PFS).

**Methods:** A randomized controlled clinical trial was conducted. Thirty-six stage I and 32 stage II patients were randomly allotted to a steroid injection and an arthroscopic treatment groups and followed up for 12 months. The outcome was evaluated using visual pain scale (VAS), the American Shoulder and Elbow Surgeon (ASES) score, shoulder active range of motion (ROM) prior to treatment, and 3 weeks and 3 and 12 months post-treatment.

**Results:** All the subjects in stages I and II PFS groups showed similar shoulder pain and function scoring before treatment. Among stage I patients, conservative treatment showed higher VAS, ASEA and ROM scores 3 weeks post-treatment. Better VAS and ASEA scores were observed in the arthroscopic treatment group with 3 months post-treatment. Patients treated by arthroscopy showed better performance on all the clinical outcomes with 12 months post-treatment, compared with conservative treatment group. In stage II patients, conservative treatment showed better therapeutic effects compared with arthroscopic treatment with 3 weeks post-treatment. Arthroscopic treatment led to better performance on backward extension and forward flexion with 3 months post-treatment. Arthroscopic patients so treated showed better performance on all the clinical outcomes with 12 months post-treatment, compared with conservative treatment group.

**Conclusion:** In early PFS patients, especially for stage II cases, arthroscopic treatment can better improve shoulder joint ROM, relieve pain, and enhance function, compared with steroid injection treatment.

Copyright © 2019, Taiwan Society of Geriatric Emergency & Critical Care Medicine.

## 1. Introduction

Frozen shoulder, also called adhesive capsulitis, causes pain and range of motion (ROM) limitation in the shoulder. It mainly occurs in 40 to 60 years old women. Its incidence is between 2% and 5%.<sup>1</sup> There is no significant difference between the incidences on the left and right sides. However, about 10% of the patients show frozen shoulder symptoms on the contralateral side within 5 years of the onset of the disease in the ipsilateral shoulder joint.<sup>2</sup> American Shoulder and Elbow Surgeons (ASES) have defined frozen shoulder as adhesive capsulitis caused by glenohumeral joint stiffness. The pathology of frozen shoulder involves a chronic inflammatory response with fibroblastic proliferation, accompanied by some transformation of fibroblasts into myofibroblasts.<sup>3</sup> Thickening of the coracohumeral ligament and contracture of rotator interval after chronic inflammation are also thought to be pathologically crucial.<sup>4</sup> The disease can be categorized into primary and secondary frozen shoulders based on pathological characteristics. Primary frozen shoulder is also called idiopathic frozen shoulder. Its etiology and

pathogenesis are still unclear.<sup>5</sup> Secondary frozen shoulder usually occurs in a manner secondary to ipsilateral upper limb trauma and operation, or systemic diseases, e.g., diabetes, hyperthyroidism, hypothyroidism, cardiovascular diseases and Parkinson's disease.<sup>6</sup>

Primary frozen shoulder is considered to be a self-limited disease with the whole course of the disease being about 12–42 months with an average time increasing upto 30 months if it is left untreated. Even if the condition is restored to the greatest possible extent, about 60% cannot recover to the normal state. The ipsilateral shoulder ROM is lower than that on the contralateral side, with some patients even suffering permanently from ROM limitation. In a prospective study on 41 frozen shoulder patients for 3 to 10 years, 39% of the patients recovered totally, 54% showed limitation of ROM, and 7% displayed shoulder joint dysfunction.<sup>7</sup> In a 7-year follow-up of 68 frozen shoulder patients, one third showed limitation in the measurement of objective ROM on the ipsilateral side, with half suffering from persistent pain and stiffness.<sup>8</sup>

Intra-articular steroid injection is a commonly used conservative intervention for frozen shoulder. Its strong anti-inflammatory effect leads to acceptable short-term outcomes in pain relief and functional improvement. In their meta-analysis, Sun et al. reported that intra-articular steroid injection significantly improved shoulder function both over the short- (4 to 6 weeks) and mid-terms (12 to 16

<sup>\*</sup> Corresponding author.

E-mail addresses: [drwanghaiming@126.com](mailto:drwanghaiming@126.com) (H. M. Wang)  
Haiming Wang and Yaohua He are co-corresponding authors

weeks). However, long-term (24 to 26 weeks) evidence is still weak.<sup>9</sup> Arthroscopic capsular release, a kind of surgical intervention, used to be applied to patients resistant to conservative treatment. It resulted in a persistent efficacy in relieving pain and improving ROM for 7 years.<sup>10</sup> It also led to significant improvement 6 weeks of the operation.<sup>11</sup>

However, to date, there is no study providing evidence comprising the efficacy of these two interventions for treating stage I or stage II frozen shoulder. The present randomized controlled clinical study seeks to evaluate the short-term (3 weeks), mid-term (3 months) and long-term (12 months) therapeutic effects of intra-articular steroid injection and arthroscopic capsular release in treatment of patients with stage I and stage II primary frozen shoulder.

## 2. Materials and methods

This study was approved by the Ethical Committee of Shanghai 6th People's Hospital. Informed consent was obtained from all the subjects included in the study.

### 2.1. Subjects

The patients were classified into stage I and stage II as defined by Nevaiser.<sup>1</sup> X-ray and MRI of the shoulder were taken before enrolling patients for diagnosis. Intra-articular local anesthesia was performed on patients with overlapping symptoms between stages. The patients with normal or only slightly limited shoulder motion after intra-articular local anesthesia were classified as stage I. Otherwise or if intra-articular anesthesia did not apparently improve the range of shoulder motion, their condition was defined as stage II.

Sixty-eight patients (45 female and 23 male) diagnosed with stage I or II idiopathic frozen shoulder in the Department of Orthopedic and Sports Medicine of Shanghai 6th People's Hospital

from June 2014 to August 2015 were recruited. Patients aged  $62.7 \pm 1.9$  years were followed up for  $1.0 \pm 0.2$  years (12-14 months). Thirty-six cases were in stage I and the remaining 32 cases were in stage II. There were no significant differences in the evaluations before operation between conservative treatment group and arthroscopic release treatment group in stage I and stage II patients, respectively (Table 1).

Inclusion criteria: (1) shoulder joint pain for 3 to 9 months;<sup>12</sup> (2) able to tolerate conservative intervention, surgical intervention and rehabilitation training; (3) normal joint space and shape of caput humeri in X-ray reports in shoulder joint anterior position and supraspinatus outlet view. Exclusion criteria: (1) allergic to drug injections; (2) diabetes complications, severe cardiovascular diseases, blood diseases, nervous system diseases, and tumors; (3) rheumatoid arthritis; (4) history of cervical spondylopathy; (5) history of trauma, dislocation and operation in the shoulder joint and ipsilateral upper limb; (6) osteoarthritis and calcific tendinitis in shoulder joint; (7) infectious diseases in shoulder joint; (8) definite injuries in rotator cuff and labrum tear in shoulder joint MRI examination. The inclusion and exclusion procedures are described in Fig. 1.

The patients were randomized into 2 groups according to computer-generated blocked-randomization numbers (<http://www.randomizer.org>). After arthroscopic confirmation of inclusion and exclusion criteria, the surgical procedure would be determined by a random number taken from a sealed envelope at the time of operation. All the patients were subjected to blind treatment, but informed of the advantages, disadvantages of both treatments, and possible risks and complications of the study.

### 2.2. Treatments

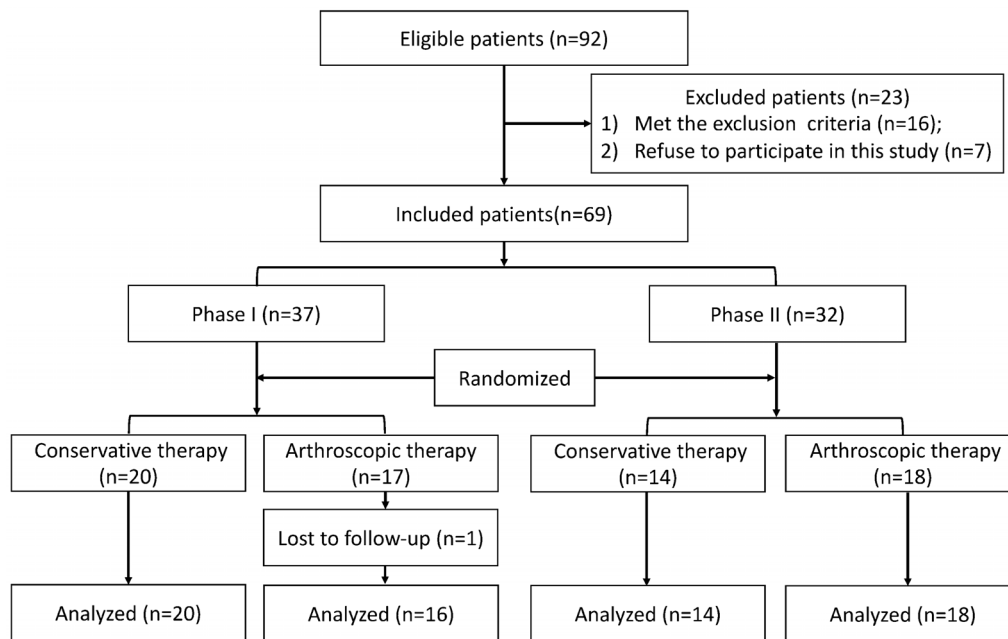
#### 2.2.1. Intra-articular steroid injection

Patients received drug injections in the capsule of glenohumeral

**Table 1**  
Evaluation of patients with stage I and II primary frozen shoulder before receiving treatments.

	Group A	Group B	t value	p value
<b>Stage I</b>				
Number	20	16		
Age (SD) year	53.60 (1.25)	53.25 (2.11)		0.88
Female (%)*	14 (70%)	11 (68.75%)		> 0.05
Left shoulder (%)*	5 (25%)	6 (37.50%)		> 0.05
Initial clinical score				
VAS for pain	7.43 ± 0.20	7.32 ± 0.20	0.39	0.70
ASES	64.31 ± 0.90	65.22 ± 1.80	0.47	0.64
Initial range of motion, deg				
Backward extension	138.52 ± 2.50	140.0 ± 2.90	0.39	0.70
Forward flexion	129.51 ± 2.70	129.42 ± 3.01	0.03	0.98
Internal rotation	35.53 ± 1.53	44.02 ± 1.13	0.32	0.75
External rotation	35.02 ± 1.54	44.5 ± 1.13	0.72	0.48
<b>Stage II</b>				
Number	14	18		
Age (SD) year	52.71 (2.20)	54.33 (2.00)		0.59
Female n (%)*	9 (64.29%)	11 (61.11%)		> 0.05
Left shoulder n (%)*	5 (35.71%)	7 (38.89%)		> 0.05
Initial clinical score				
VAS for pain	9.02 ± 0.20	9.04 ± 0.23	0.00	> 0.99
ASES	58.33 ± 2.04	55.72 ± 1.74	1.01	0.32
Initial range of motion, deg				
Backward extension	58.62 ± 4.07	58.91 ± 3.62	0.06	0.95
Forward flexion	78.64 ± 3.83	81.14 ± 3.80	0.47	0.64
Internal rotation	17.92 ± 2.14	17.85 ± 1.93	0.03	0.98
External rotation	7.92 ± 3.91	8.32 ± 3.50	0.09	0.93

Group A, conservative treatment group; Group B, arthroscopic treatment group; SD, standard deviation; VAS, visual analog scale; ASES, American Shoulder and Elbow Surgeons; \*, data were analyzed by *chi-square* test, and the rest of data were analyzed by independent *t*-test.



**Fig. 1.** Flow chart illustrating patients enrollment and randomization according to Consolidated Standards of Reporting Trials (CONSORT) criteria.

joint and subacromial space on day 1, 3 weeks and 6 weeks. (1) Intracapsular puncture of glenohumeral joint: 5 ml 2% lidocaine (Hualu Pharmaceutical Co. Ltd., Shangdong, China), 25 mg triamcinolone acetonide acetate (Xudong haipu pharmaceutical Co. Ltd., Shangdong, China), and 25 mg (2.5 ml) sodium hyaluronate (Jing feng pharmaceutical Co. Ltd., Shangdong, China) were mixed and injected into the glenohumeral joint cavity. (2) Subacromial space puncture: 5 ml 2% lidocaine (Hualu Pharmaceutical Co. Ltd., Shangdong, China) mixed with 25 mg triamcinolone acetonide acetate (Xudong haipu pharmaceutical Co. Ltd., Shangdong, China) was injected into subacromial space. All the patients were under general anesthesia and the injections were performed by the same group of physicians.

### 2.2.2. Arthroscopic capsular release

Patients were placed in lateral decubitus position on the contralateral side, with 45° traction by abduction frame. (1) Clean and release of glenohumeral joint: an arthroscopic capsular release was initiated by inserting an arthroscope into the glenohumeral joint via a standard posterior portal. In some cases, contracture and adhesion occurred in articular capsule humeri. When the joint space was too narrow for the insertion into glenohumeral joint from posterior portal, an extra posterior portal was added 2 cm below the standard posterior portal. Through double posterior portals, posterior articular capsule of shoulder joint was released, followed by release of the region (around 1.0–1.5 cm in width) from saccus axillaris to the anterior part of articular capsule using a plasma knife (Smith & Nephew, Suzhou, China) along *cavitas glenoidalis*. The plasma knife appressed the bone surface, avoiding injuring the axillary nerve. The glenohumeral joint cavity was examined through posterior portal. Under the arthroscope, a spinal needle was inserted medially to the biceps tendon, laterally to the coracoid process, and superiorly to the superior border of subscapularis, to establish the anterior portal. The inflammatory proliferative synovium in articular capsule was cut using shaver and plasma knife. The inflammatory tissues between the superior border of subscapularis and along head of the biceps tendon, including thickened and adhesive articular capsule as well as coracohumeral ligament,

were released using a plasma knife. The release headed medially to lateral but not across the coracoid process, avoiding injuring the neurovascular bundle. Biceps tenotomy and tenodesis were performed when dislocation, abrasion or notable inflammation were observed in the long head of the biceps tendon. The inflammatory synovium of subscapularis tendon was then removed. The subscapularis tendon, superior, middle or the anterior part of inferior glenohumeral ligament, were merged with saccus axillaris release wound surface. Care should be taken to protect circumferential cartilage when the operation is performed within 10–15 mm medial to superior circumferential cartilage. Caution is also needed to avoid damaging the neurovascular bundle of scapula. (2) Cleaning and decompression of subacromial space: the arthroscope was inserted towards anterolateral angle of acromion through posterior portal, to expose the subacromial space. The lateral portal was then established under the arthroscope using a spinal needle to detect acromion impingement and rotator cuff injury. Acromioplasty was performed if coracoacromial ligament abrasion, osteophyte and hyperplasia in anterior one third of acromion were detected. Congestive and adhesive subacromial bursa was totally removed in the following region: laterally crossing greater tuberosity to deltoid bursa; medially reaching supraspinatus tendon-belly junction; anteriorly opening rotator interval, cleaning and releasing to coracoid process, merging with the release of superior border of subscapularis; posteriorly cleaning and releasing to spine scapula.

In this study, no complications were reported in either conservative intervention group or arthroscopic capsular release group.

### 2.3. Rehabilitation

Diclofenac sodium sustained release tablets (75 mg per day; Voltaren, Novartis, Beijing, China) were prescribed for 5–7 days after conservative treatment and arthroscopic operation. Under the supervision of an experienced physical therapist, practices of active and passive ROM in shoulder joint were taken twice per week for 6 weeks with regular physical exercises being undertaken twice per day.

2.4. Outcome measurement

Each patient was assessed before treatment, 3 weeks, 3 months, and 12 months after operation, using the American Shoulder and Elbow Surgeons (ASES) and the visual analog scale (VAS) pain scoring system. Range of motion (ROM)—backward extension, forward flexion, internal rotation, and external rotation—was measured using goniometer. A VAS for pain severity at rest (0, no pain; 10, the most severe pain) was given to all patients at each visit. For the purposes of analysis, the vertebral level was numbered serially: 0 for any level below the sacral region and 1 point added for each level above the sacrum. All data were collected prospectively by a clinical researcher who was blinded to current study. Patients were blinded during the assessment.

2.5. Statistical analysis

All quantitative data were presented as mean ± SD, and analyzed by SPSS 13.0 (IBM, New York). Independent *t*-test and *chi-square* test were performed, and *p* < 0.05 was taken as statistically significant.

3. Results

In patients with stage I primary frozen shoulder, similar shoulder pain and function were observed before treatment. Three weeks after treatment, conservative treatment group showed better performance on VAS for pain, ASEA score and ROM compared with arthroscopic treatment group. Three months after treatment, arthroscopic treatment led to better performance on VAS for pain and ASEA score compared with conservative treatment group, whereas no significant difference in ROM was observed between the two groups. Twelve months after treatment, arthroscopic treatment group showed better performance on all the parameters measured, compared with conservative treatment group (Fig. 2).

In patients with stage II primary frozen shoulder, similar shoulder pain and function were observed before treatment. Three weeks after treatment, conservative treatment group showed better performance on VAS for pain, ASEA score and ROM when compared with arthroscopic treatment group; 3 months after treatment, no significant difference was observed in VAS for pain, ASEA score, internal rotation degree and external degree between two groups, while arthroscopic treatment group displayed better performance on backward extension and forward flexion when compared with conservative treatment group; 12 months after treatment, arthroscopic treatment led to better performance on all the clinical outcomes compared with conservative treatment (Fig. 3).

4. Discussion

In this study, the results showed that in patients with stage I primary frozen shoulder. Three weeks after steroid injection, the pain relieving effects were more obvious than those received arthroscopic treatment. It has been reported that intra-articular injection of methylprednisolone and lidocaine lead to improvement in joint performance in short-term (2–3 weeks), whereas the therapeutic effects are similar to those of control group when evaluated at 15 weeks and 6 months after treatment.<sup>13</sup> Additional application of steroid to regular treatments using non-steroidal anti-inflammatory drug combined with physical therapy helped mitigate pain, with the relieving effects lasting no more than 6 months.<sup>14</sup> During arthroscopic cleaning of shoulder joint synovium, sustained washing of

normal saline helped restrain the influence of cytokines on inflammatory reactions and joint capsular fibrosis, to control the shoulder joint pain for the long run.<sup>15</sup> It was found that subacromial fibrosis complicated with synovial hypertrophy was also a cause of shoulder joint pain, but arthroscopic cleaning and decompression of subacromial space could effectively relieve the pain. Moreover, in patients suffering from dislocation, abrasive wear or inflammation on the long head of biceps tendon, biceps tenotomy and tenodesis could also help relieve the pain.<sup>16</sup> Nevertheless, the pain relieving effects in arthroscopic capsular release treated patients may not be significant shortly after operation, since traumatic inflammation occurs after operation. However, arthroscopic capsular release treatment showed better pain relieving effects compared with steroid injection 3 months after operation, which lasted for 12 months. In patients with stage II primary frozen shoulder, the therapeutic effects of steroids might be lower probably due to the exacerbation of capsular inflammation and capsular fibrosis. Therefore, in these patients, the short-term effects of steroid injection were limited but their long-term effects were inferior to those of arthroscopic treatment.

The ASES scoring system was used in the present study to evaluate the shoulder joint function. In this scoring system, the self-feeling and self-care ability of the patients before and after treatment were evaluated while ensuring good objectivity. In stage I and II primary frozen shoulder patients, 3 weeks after treatment, the conservative treatment group showed higher ASES scores compared

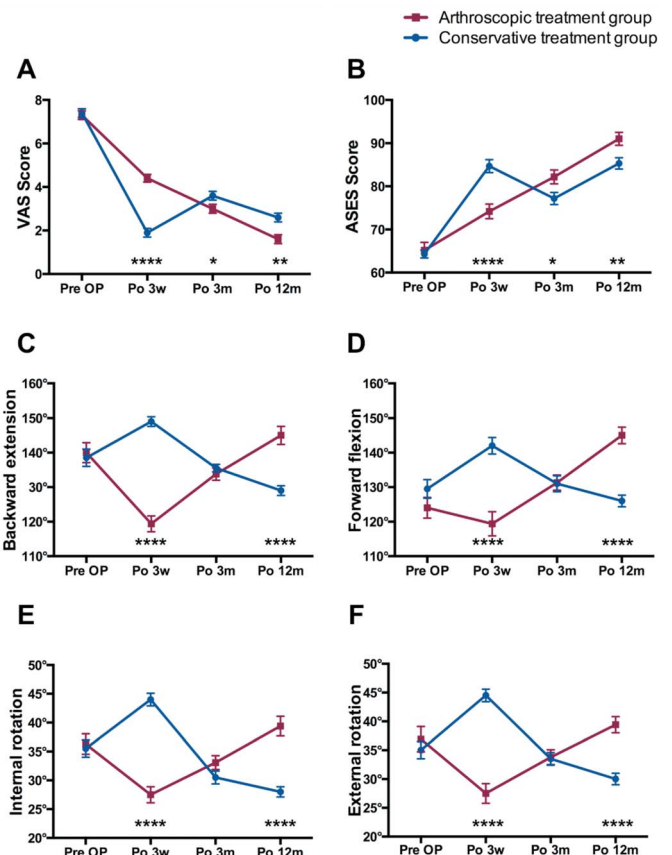
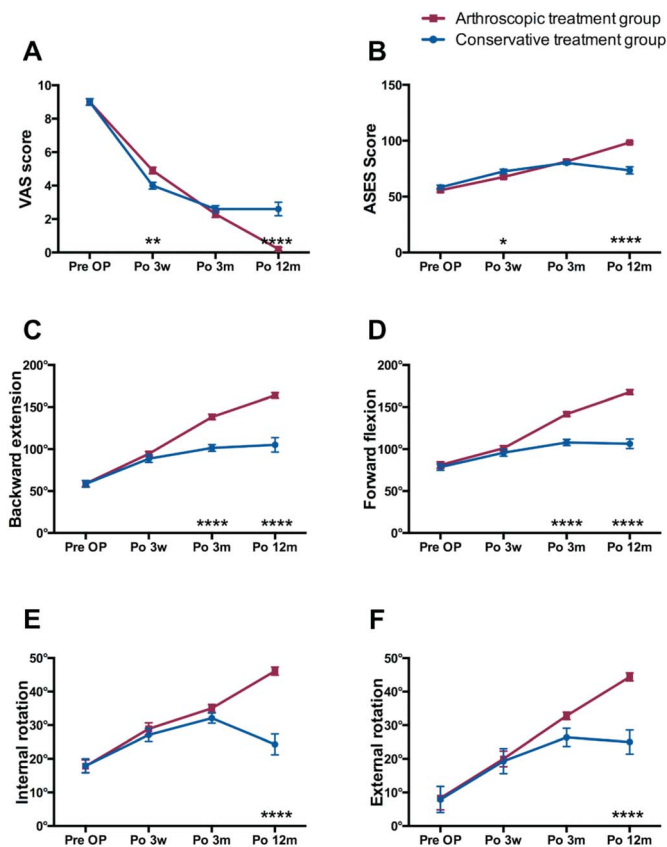


Fig. 2. Comparison of therapeutic effects between conservative treatment and arthroscopic treatment on stage I primary frozen shoulder. Evaluations of shoulder pain and function using VAS score (A), ASES score (B), backward extension (C), forward flexion (D), internal rotation (E) and external rotation (F) are shown. VAS, visual pain scale; ASES, American Shoulder and Elbow Surgeon; OP, operation; Po, post operation; w, week; m, month. \* *p* < 0.05, \*\* *p* < 0.01, \*\*\* *p* < 0.0001, arthroscopic treatment group vs. conservative treatment group, independent *t*-test.



**Fig. 3.** Comparison of therapeutic effects between conservative treatment and arthroscopic treatment on stage II primary frozen shoulder. Evaluations of shoulder pain and function using VAS score (A), ASES score (B), backward extension (C), forward flexion (D), internal rotation (E) and external rotation (F) are shown. VAS, visual pain scale; ASES, American Shoulder and Elbow Surgeon; OP, operation; Po, post operation; w, week; m, month. \*  $p < 0.05$ , \*\*  $p < 0.01$ , \*\*\*\*  $p < 0.0001$ , arthroscopic treatment group vs. conservative treatment group, independent *t*-test.

with the arthroscopic treatment group, indicating that steroid injection had a better short term therapeutic effect. It was apparent that intra-articular injection of steroids helps early control of pain in primary frozen shoulder patients. As a result, in early intervention, stage I patients treated with steroids showed pain relief and increased ASES score. However, 3 months after giving treatment to stage I patients, and 1 year after the treatment to all the subjects, arthroscopic treated group showed superior responses to conservative treatments, indicating that arthroscopic treatment could improve the mid-term and long-term life quality of patients better.

Our study found that arthroscopic treatment showed better shoulder joint ROM than conservative treatment in stage I patients 1 year after treatment and in stage II patients 3 months and 1 year after treatment. It has been reported that contracture of coracohumeral ligament and rotator interval are the main pathological causes behind shoulder stiffness.<sup>4</sup> Since a limitation of shoulder external rotation is seen most often in frozen shoulder cases and the coracohumeral ligament is the major factor to restrain shoulder external rotation, one may speculate that the coracohumeral ligament in rotator interval might be the primary focus of a frozen shoulder. MRI examinations have proved the existence of significant thickening of coracohumeral ligament and rotator interval capsule, with the fat triangle between coracohumeral ligament and coracoid process disappearing totally<sup>17</sup> While operating to open and release a frozen shoulder, fascicular thickening and contracture of coracohumeral ligament were observed.<sup>18</sup> Under the arthroscope, the

coracohumeral ligament and rotator interval could be released in a pertinent manner to improve the external rotation function. Sub-acromial bursitis is another typical pathological change of primary frozen shoulder that mainly hinders forward flexion, upthrow and external rotation of shoulder joint. While performing arthroscopic release of adhesivtissues, simultaneous subacromial bursa cleaning and acromioplasty could help post-operational function recovery, especially external rotation function,<sup>19</sup> During the process of arthroscopic surgery, the joint capsule undergoes sustained perfusion of high pressure normal saline; the even and gentle fluid pressure helps isolate intra-capsular adhesions,<sup>15,16</sup> which gradually dilate the capsule and restore articular cavity volume to some extent.<sup>20</sup> Moreover, cytokines plays an important role in inflammation and capsular fibrosis, so sustained generation of cytokines stimulate fibroblast production and lead to fibrosis.<sup>21</sup> When arthroscopic operation is performed with continuous normal saline perfusion, the articular cavity gets cleaned. This, might be a possible reason for pain reliving and reverse of pathology after operation.

There are some limitations in this study. (1) In the present study, the follow-up period was only 12 months, therefore the therapeutic effects of the two treatments for a longer period were uncertain. It seems worthwhile for future studies to investigate their long-term effects for more than 12 months. (2) The sample size in each sub-group was relatively small. It is necessary to expand the sample size in future studies to reduce the potential for sampling error.

## 5. Conclusion

In early primary frozen shoulder patients, especially Nevaizer stage II cases, arthroscopic release of capsule, cleaning of inflammatory synovium, combined with nonsteroidal anti-inflammatory drugs and active physical therapy, could better improve shoulder joint range of motion, relieve pain, improve and daily life function, compared with steroid injection treatment.

## Conflicts of interest

There are no conflicts of interest.

## Source of support.

None.

## References

1. Neviaser AS, Hannafin JA. Adhesive capsulitis: A review of current treatment. *Am J Sports Med.* 2010;38:2346–2356.
2. Bunker TD, Anthony PP. The pathology of frozen shoulder. A Dupuytren-like disease. *J Bone Joint Surg Br.* 1995;77:677–683.
3. Tamai K, Akutsu M, Yano Y. Primary frozen shoulder: Brief review of pathology and imaging abnormalities. *J Orthop Sci.* 2014;19:1–5.
4. Ozaki J, Nakagawa Y, Sakurai G, et al. Recalcitrant chronic adhesive capsulitis of the shoulder. Role of contracture of the coracohumeral ligament and rotator interval in pathogenesis and treatment. *J Bone Joint Surg Am.* 1989;71:1511–1515.
5. Hand GC, Athanasou NA, Matthews T, et al. The pathology of frozen shoulder. *J Bone Joint Surg Br.* 2007;89:928–932.
6. Milgrom C, Novack V, Weil Y, et al. Risk factors for idiopathic frozen shoulder. *Isr Med Assoc J.* 2008;10:361–364.
7. Reeves B. The natural history of the frozen shoulder syndrome. *Scand J Rheumatol.* 1975;4:193–196.
8. Shaffer B, Tibone JE, Kerlan RK. Frozen shoulder. A long-term follow-up. *J Bone Joint Surg Am.* 1992;74:738–746.
9. Sun Y, Zhang P, Liu S, et al. Intra-articular steroid injection for frozen shoulder: A systematic review and meta-analysis of randomized

- controlled trials with trial sequential analysis. *Am J Sports Med.* 2017;45:2171–2179.
10. Le Lievre HM, Murrell GA. Long-term outcomes after arthroscopic capsular release for idiopathic adhesive capsulitis. *J Bone Joint Surg Am.* 2012;94:1208–1216.
  11. Barnes CP, Lam PH, Murrell GA. Short-term outcomes after arthroscopic capsular release for adhesive capsulitis. *J Shoulder Elbow Surg.* 2016; 25:e256–264.
  12. Griesser MJ, Harris JD, Campbell JE, et al. Adhesive capsulitis of the shoulder: A systematic review of the effectiveness of intra-articular corticosteroid injections. *J Bone Joint Surg Am.* 2011;93:1727–1733.
  13. Rizk TE, Pinals RS, Talaiver AS. Corticosteroid injections in adhesive capsulitis: Investigation of their value and site. *Arch Phys Med Rehabil.* 1991;72:20–22.
  14. Saeidian SR, Hemmati AA, Haghghi MH. Pain relieving effect of short-course, pulse prednisolone in managing frozen shoulder. *J Pain Palliat Care Pharmacother.* 2007;21:27–30.
  15. Chen J, Chen S, Li Y, et al. Is the extended release of the inferior glenohumeral ligament necessary for frozen shoulder? *Arthroscopy.* 2010;26:529–535.
  16. Pearsall AWT, Osbahr DC, Speer KP. An arthroscopic technique for treating patients with frozen shoulder. *Arthroscopy.* 1999;15:2–11.
  17. Mengiardi B, Pfirrmann CW, Gerber C, et al. Frozen shoulder: MR arthrographic findings. *Radiology.* 2004;233:486–492.
  18. Omari A, Bunker TD. Open surgical release for frozen shoulder: Surgical findings and results of the release. *J Shoulder Elbow Surg.* 2001;10: 353–357.
  19. Robinson CM, Seah KT, Chee YH, et al. Frozen shoulder. *The Journal of Bone and Joint Surgery British Volume.* 2012;94:1–9.
  20. Nicholson GP. Arthroscopic capsular release for stiff shoulders: Effect of etiology on outcomes. *Arthroscopy.* 2003;19:40–49.
  21. Hannafin JA, Chiaia TA. Adhesive capsulitis. A treatment approach. *Clin Orthop Relat Res.* 2000;95–109.